

# Prevention of Ulceration, Amputation, and Reduction of Hospitalization: Outcomes of a Prospective Multicenter Trial of Tibial Neurolysis in Patients with Diabetic Neuropathy

A. Lee Dellon, M.D., Ph.D.<sup>1,2</sup> Vickie L. Muse, R.N., B.S.N., C.D.E.<sup>2</sup> D. Scott Nickerson, M.D.<sup>3</sup> et al\*

<sup>1</sup> Department of Plastic Surgery, Johns Hopkins University, Baltimore, Maryland

<sup>2</sup> Dellon Institute for Peripheral Nerve Surgery, Peripheral Nerve Towson, Baltimore, Maryland

<sup>3</sup> Northeast Wyoming Wound Care Center, Sheridan, Wyoming

\* Contributing authors listed at the end of the article.

**Address for correspondence and reprint requests** A. Lee Dellon, M.D., Ph.D., The Exchange Bldg, Suite 18, 1122 Kenilworth Drive, Towson, MD 21204 (e-mail: ALDellon@Dellon.com).

J Reconstr Microsurg 2012;28:241–246.

## Abstract

This is the first multicenter prospective study of outcomes of tibial neurolysis in diabetics with neuropathy and chronic compression of the tibial nerve in the tarsal tunnels. A total of 38 surgeons enrolled 628 patients using the same technique for diagnosis of compression, neurolysis of four medial ankle tunnels, and objective outcomes: ulceration, amputation, and hospitalization for foot infection. Contralateral limb tibial neurolysis occurred in 211 patients for a total of 839 operated limbs. Kaplan–Meier proportional hazards were used for analysis. New ulcerations occurred in 2 (0.2%) of 782 patients with no previous ulceration history, recurrent ulcerations in 2 (3.8%) of 57 patients with a previous ulcer history, and amputations in 1 (0.2%) of 839 at risk limbs. Admission to the hospital for foot infections was 0.6%. In patients with diabetic neuropathy and chronic tibial nerve compression, neurolysis can result in prevention of ulceration and amputation, and decrease in hospitalization for foot infection.

## Keywords

- ▶ ulcers
- ▶ amputation
- ▶ diabetic neuropathy

Over the 18 years since the first publication of a retrospective, Level IV study of the results of decompression of multiple sites of peripheral nerve compression in the upper and lower extremity,<sup>1</sup> subsequent similar studies confirmed that 80% of patients can expect good relief of their pain, that 80% of the patients can expect recovery of some sensation, and that new ulcers and new amputations can be largely prevented.<sup>2–15</sup> These studies have been reviewed recently, and have in common the identification of the site of chronic nerve entrapment using the Tinel sign, surgical release of the tibial nerve in the four medial ankle tunnels, and early ambulation.<sup>16,17</sup> Three separate basic science laboratories have documented in animal models of diabetes that the peripheral

nerve is susceptible to compression and that decompression will improve peripheral nerve function in the presence of a diabetic neuropathy.<sup>17–22</sup> The controversies related to this approach have also been reviewed recently.<sup>23</sup>

It is the purpose of this report to describe the results of the first prospective, multicenter nonrandomized trial of neurolysis of the tibial nerve and its branches in the tarsal tunnel, with the data collection being done prospectively and analyzed prospectively with Kaplan–Meier proportional hazard analysis. The study was done sufficiently long and with a sufficiently large well-defined patient population to demonstrate the outcome of this approach upon ulcer and amputation occurrence, and hospitalization for foot infections.

received  
August 13, 2011  
accepted  
October 16, 2011  
published online  
March 12, 2012

Copyright © 2012 by Thieme Medical Publishers, Inc., 333 Seventh Avenue, New York, NY 10001, USA.  
Tel: +1(212) 584-4662.

DOI <http://dx.doi.org/10.1055/s-0032-1306372>.  
ISSN 0743-684X.

## Methods

This study was designed as a prospective, multicentered study, with a well-defined sample of patients and well-defined outcomes.

Each of the 38 surgeons participating in this study, were trained in an Advanced Lower Extremity Peripheral Nerve Surgery Workshop so that each surgeon used the same operative technique as previously described and reviewed,<sup>23</sup> and each used the same outcome measurements.

### Inclusion Criteria

1. Patient had to have diabetes requiring medication for glycemic control.
2. The patient's diabetes was in good glycemic control.
3. Patient had to have symptomatic diabetic neuropathy, defined as a diffuse, symmetrical, distal, large fiber, and polyneuropathy.<sup>24–26</sup>
4. This neuropathy had to be documented at least by neurosensory testing with the pressure-specified sensory device.<sup>27–30</sup>
5. If the patient had pain, then there had to be a trial and failure of neuropathic pain medication.<sup>31,32</sup>
6. Patients had sufficient lower extremity blood supply, as demonstrated either by a palpable dorsalis pedis or posterior tibialis pulse, or, in the absence of a palpable pulse, an ankle/brachial index >0.70.
7. Absence of pedal edema.
8. Physical findings consistent with a chronic nerve compression at the known sites of anatomic narrowing, that is, common peroneal nerve at the fibular tunnel, deep peroneal nerve over the dorsum of the foot, and tibial nerve compression in the tarsal tunnel, as demonstrated by a positive Tinel sign.<sup>8</sup>
9. Patient had to be sufficiently healthy to have a 2-hour general anesthetic.

### Exclusion Criteria

1. Weight over 300 pounds.
2. Previous lower extremity peripheral nerve surgery.
3. Previous amputation.
4. Presence or absence of ulcerations was not an exclusion criteria but was noted for substratification data analysis.

### Outcome Analysis

1. Presence or absence of ulceration anywhere on the operated foot.
  2. Any lower extremity amputation in the postoperative period on the operated foot.
  3. Hospitalization for infection in the operated foot.
- Statistical analysis was done using Kaplan–Meier proportional hazard analysis and student's *t*-test.

## Results

At the time of data analysis, 628 patients had been enrolled in the study and followed for at least 1 year. Of these, 211 had the

contralateral limb operated upon for a total number of operated limbs of 839. Of the 628 patients, 465 (74%) had pain >5 at the initial visit, and 152 of these patients had a second limb operated upon for a total of 617 operated limbs with pain. Data analysis extends from the initial onset to 3.5 years postoperatively.

The results for appearance of a new ulceration are given in ►Fig. 1. Of the 782 limbs that were operated and had never had a previous ulceration, just 2 patients (0.3%) developed an ulceration at 1.5 years and this percentage did not increase in the remaining period of observation.

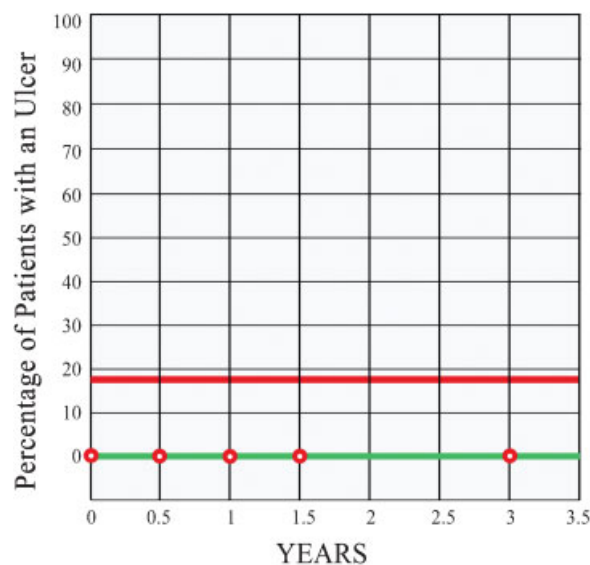
The results for recurrent ulceration in those patients who had a pre-existing ulcer or healed ulcer are given in ►Fig. 2. Of the 57 limbs that had a previous history of ulceration, just 2 had a recurrent ulceration (3.8%) over the period of observation.

The results for occurrence of any amputation are given in ►Fig. 3. Of the 839 limbs that were operated upon, a toe amputation occurred in 1 patient (0.2%).

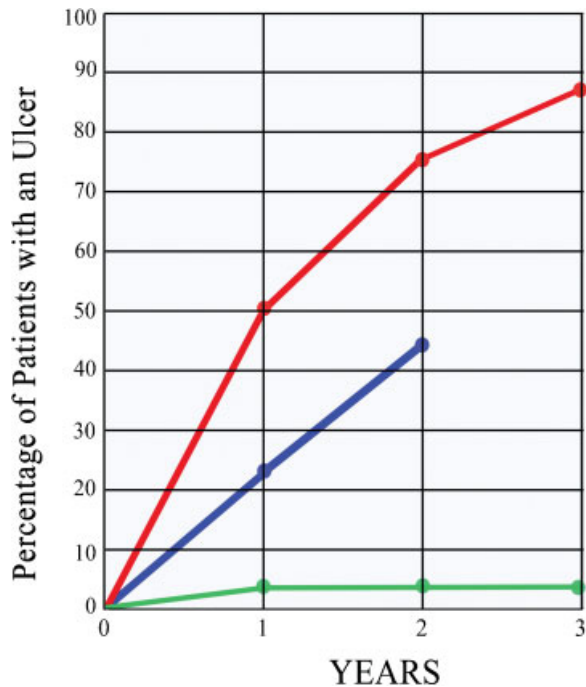
The results for hospitalization for foot infection are given in ►Fig. 4. Of the 628 patients, 4 (0.6%) were admitted to the hospital for treatment of a foot infection that was not related to the surgical healing process over the period of observation.

## Discussion

The results of this study demonstrate that patients with symptomatic neuropathy related to diabetes can have unrecognized lower extremity chronic nerve compression in the four medial ankle tunnels, and, when this is present, neurolysis of the tibial nerve predictably will prevent new ulceration and amputation, and reduce hospitalization from foot infections. The patients in this study remained diabetic,



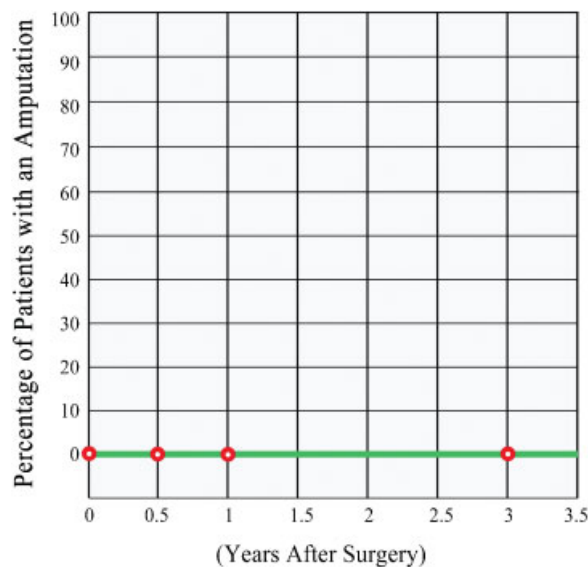
**Figure 1** Outcome: New ulceration. Of the 782 limbs that were operated upon that had never had a previous ulceration, just two patients (0.3%) developed an ulceration at 1.5 years and this percentage did not increase in the remaining period of observation (green line). The expected lifetime occurrence of ulceration in this population of patients is 15% (red line).



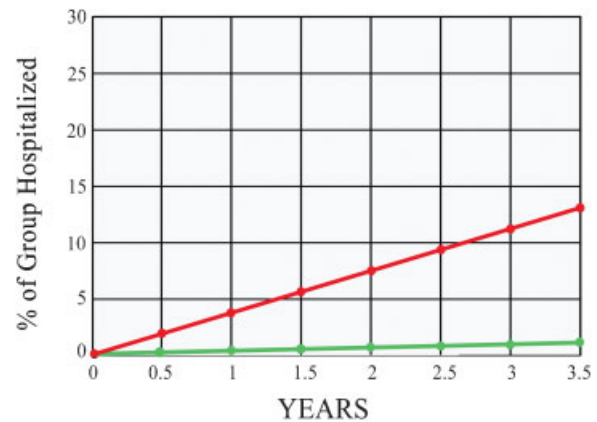
**Figure 2** Outcome: Recurrent ulceration. Of the 57 limbs that were operated upon that had a previous ulceration, 2 (3.8%) recurred (green line). It is expected that from 50 to 60% of healed ulcers will recur (red line), and with intensive primary foot care the recurrence rate can be reduced to 25 to 30% (blue line).

they just no longer had compression of their tibial nerve at the ankle level, and this permitted recovery of sensation with all its protective benefits.

Prevention of ulceration and amputation in patients with diabetes remains the elusive quest. About 20 years ago, reviews of the medical literature documented that the incidence of ulceration is 2.5% per year and its prevalence is 15%.<sup>33-36</sup> Despite attempts to decrease the number of



**Figure 3** Outcome: Amputation. Of the 839 limbs that were operated upon, an amputation occurred in one patient (0.2%). The expected number of amputations would be 10 to 15%.



**Figure 4** Outcome: Hospitalization for foot infection. Of the 628 patients that were operated upon, 4 (0.6%) were admitted to the hospital for treatment of a foot infection that was not related to the surgical healing process (green line). This may be compared with the published results from another study of the best available, intensive primary foot care, in which, of 1666 patients followed for 2 years, 9% developed a foot infection, and 3.7% of patients required hospitalization (red line).<sup>49</sup>

amputations in the United States of America by various strategies from better glucose control, to monitoring screening exams for impaired sensibility, the number of amputations continued to increase from 54,000 in 1990,<sup>37</sup> to 92,000 in 1999.<sup>38</sup> More recently, from 2000 to 2002, an estimated 11.7% of U.S. adults with diabetes still had a history of foot ulcer.<sup>39</sup> This has been the basis for the teaching that the natural history of diabetic neuropathy is progressive and irreversible. However in 2004, based upon the hypothesis that some of the symptoms of diabetic neuropathy were due to superimposed nerve compressions, the impact of tibial neurolysis at the ankle on the development of ulcers and amputations in both the operated and the contralateral, non-operated limb was evaluated in a retrospective analysis of 50 diabetics a mean of 4.5 years (range 2 to 7 years) from the date of surgery. No ulcers or amputations occurred in the index limb of these patients. In contrast, there were 12 ulcers and 3 amputations in 15 different patients in the contralateral limbs. This difference was significant at the  $p < 0.001$  level. It was concluded that decompression of lower extremity nerves in diabetics with chronic nerve compression changes the natural history of this disease, representing a paradigm shift in health care costs.

Review of the world literature today with respect to what has happened during the past twenty years with regard to implementation of medical programs to prevent ulcers and amputation remains discouraging. The incidence of foot ulcerations is 1.9 to 4.1% per year, with a prevalence of 4 to 18% of the diabetic population.<sup>40-42</sup> The lifetime risk for developing an ulcer may still be as high as 25%<sup>40</sup> The situation for amputations is quite similar. In diabetic patients, the incidence of both major and minor lower-extremity amputations ranges from 2.1 to 13.7 per 1000.<sup>43</sup> While certain well controlled populations, such as in Norway, have demonstrated improvement in the incidence of diabetic major lower extremity amputations from 4.0 to 2.4 per 1000 diabetics per

year through an intense program of patient education and examination,<sup>44</sup> most reports are still discouraging. In the United Kingdom, in 2008, the absolute number of diabetes-related amputations increased by 14.7%.<sup>45</sup> In that study, while the incidence of amputations decreased by 9.1%, the absolute magnitude of the amputations was still at 2.5 per 1000 people with diabetes, and the incidence of minor and major amputations did not significantly change. In Saudi Arabia, in 2010, comparison of two small (20-patient) cohorts of patients, with and without instruction in foot care, saw the amputation rate remain at 69%.<sup>46</sup> In the United States, in 2010, a study was reported that demonstrated that while the number of limb losses decreased, the frequency of total amputations increased from 24 in the first year of the study to 46 in the second year of the study.<sup>47</sup>

These disturbing statistics highlight the need to consider evaluating diabetics with neuropathy for the presence of chronic nerve compression of the tibial nerve in the tarsal tunnels. This failure to achieve significant change by medical management should be contrasted with the results of the present surgical study which show an incidence of new ulcerations of just 0.6% and recurrent ulcerations of just 3.8%. A recent surgical review<sup>48</sup> of recurrent ulcerations in a cohort of 75 feet in 57 patients that had a neurolysis of the tibial nerve in the four medial ankle tunnels, the same technique as reported in the present study, found a recurrence rate of 4.9% with a mean follow-up of 2.9 years (range 1–13 years), again demonstrating the significant improvement that can be achieved if a proactive approach to restoring sensation is adopted for the management of this problem.

This is the first study to report the effect of neurolysis of the tibial nerve in the tarsal tunnel on the outcome of hospitalizations for foot infections. As a comparison, consider the intensive program of preventive foot care described by Lavery et al in 2006.<sup>49</sup> Among 1666 diabetics with neuropathy, who were receiving regular podiatric foot care and preventive techniques, 9% developed foot infections and 3.7% required hospitalization for treatment of foot infections over their 2-year time period of observation. This may be contrasted to the results of the present study (→ Fig. 4) in which just 0.6% of patients who had neurolysis of the tibial nerve required hospitalization for treatment of foot infections over the 2-year time period of observation.

#### Note

Presented to American Diabetes Association 66th Scientific Sessions meeting, San Francisco, 2000.

#### Conflict of Interest

A. Lee Dellon, M.D., Ph.D., owns Sensory Management Services, LLC, which markets the Pressure-Specified Sensory Device™.

#### \*Contributing Authors

Thomas Akre, DO, Orthopedic Surgery, Mishasawka, Indiana.

Sharon R. Anderson, DPM, Podiatric Foot & Ankle Surgery, Rolla, Missouri.

Steve L. Barrett, DPM, MBA, Podiatric Foot & Ankle Surgery, Houston, Texas.

Kent R. Biddinger, MD, Orthopedic Foot & Ankle Surgery, Midland, Michigan.

Peter J. Bregman, DPM, Podiatric Foot & Ankle Surgery, Tewksbury, Massachusetts.

Bryan P. Bullard, DPM, Podiatric Foot & Ankle Surgery, Amarillo, Texas.

Damien M. Dauphinee, DPM, Podiatric Foot & Ankle Surgery, Denton, Texas.

James M. DeJesus, DPM, Podiatric Foot & Ankle Surgery, Naugatuk, Connecticut.

Ramon A. DeJesus, MD, Plastic Surgery, Bel Air, Maryland.

A. Lee Dellon, MD, Plastic Surgery, Johns Hopkins University, Baltimore, Maryland.

Ivica Ducic, MD, Plastic Surgery, Georgetown University, Washington, DC.

Jeffery Dunkerly, DPM, Podiatric Foot & Ankle Surgery, York, Pennsylvania.

Michael R. Galina, DPM, Podiatric Foot & Ankle Surgery, Winter Garden, Florida.

Virginia Hung, MD, Plastic Surgery, Winchester, Massachusetts.

Dolf R. Ichtertz, MD, Orthopedic Hand Surgery, North Platte, Nebraska.

Michael F. Kutka, MD, Plastic Surgery, Newburyport, Massachusetts.

Richard P. Jacoby, DPM, Podiatric Foot & Ankle Surgery, Scottsdale, Arizona.

J. Barry Johnson, DPM, Podiatric Foot & Ankle Surgery, Winston-Salem, North Carolina.

David W. Mader, DPM, Podiatric Foot & Ankle Surgery, Naugatuk, Connecticut.

Christopher T. Maloney, Jr, MD, Plastic Surgery, Tucson, Arizona.

Peter J. Mancuso, DPM, Podiatric Foot & Ankle Surgery, Brentwood, New York.

R. Craig Martin, DPM, Podiatric Foot & Ankle Surgery, York, Pennsylvania.

Rick F. Martin, DPM, Podiatric Foot & Ankle Surgery, York, Pennsylvania.

Brian A. McDowel, DPM, Podiatric Foot & Ankle Surgery, Carmichael, California.

Vito J. Rizzo, DPM, Podiatric Foot & Ankle Surgery, Bayshore, Long Island, NY.

Michael Rose, MD, Plastic Surgery, Shrewsbury, New Jersey.

Gedge D. Rosson, MD, Plastic Surgery, Johns Hopkins University, Baltimore, Maryland.

Bruce B. Shafiroff, MD, Plastic Surgery, Syracuse, New York.

Jerome K. Steck, DPM, Podiatric Foot & Ankle Surgery, Tucson, Arizona.

Raymond G. Stolarski, DPM, Podiatric Foot & Ankle Surgery, Cincinnati, Ohio.

Patrick Swier, MD, Plastic Surgery, Lewes, Delaware.  
Tatiana A. Wellens-Bruschayt, DPM, PhD, Pod. Foot & Ankle Surg., Winter Haven, Fla.

Bronwyn Wilke, DPM, Podiatric Foot & Ankle Surgery, York, Pennsylvania.

Eric H. Williams, MD, Plastic Surgery, Johns Hopkins University, Baltimore, Maryland.

Michael A. Wood, DPM, Podiatric Foot & Ankle Surgery, Chicago, Illinois.

William A. Wood, DPM, Podiatric Foot & Ankle Surgery, Chicago, Illinois.

Michael P. Younes, DPM, Podiatric Foot & Ankle Surgery, York, Pennsylvania.

Fuat Yuksel, MD, Plastic Surgery, Istanbul, Turkey.

## References

- Dellon AL. Treatment of symptomatic diabetic neuropathy by surgical decompression of multiple peripheral nerves. *Plast Reconstr Surg* 1992;89(4):689-697, discussion 698-699
- Wieman TJ, Patel VG. Treatment of hyperesthetic neuropathic pain in diabetics. Decompression of the tarsal tunnel. *Ann Surg* 1995;221(6):660-664, discussion 664-665
- Hollis Caffee H. Treatment of diabetic neuropathy by decompression of the posterior tibial nerve. *Plast Reconstr Surg* 2000;106(4):813-815
- Aszmann OC, Kress KM, Dellon AL. Results of decompression of peripheral nerves in diabetics: a prospective, blinded study. *Plast Reconstr Surg* 2000;106(4):816-822
- Tambwekar DS. Extended neurolysis of the posterior tibial nerve to improve sensation in diabetic neuropathic feet. *Plast Reconstr Surg* 2001;108(5):1452-1453
- Wood WA, Wood MA. Decompression of peripheral nerves for diabetic neuropathy in the lower extremity. *J Foot Ankle Surg* 2003;42(5):268-275
- Biddinger KR, Amend KJ. The role of surgical decompression for diabetic neuropathy. *Foot Ankle Clin* 2004;9(2):239-254
- Lee CH, Dellon AL. Prognostic ability of Tinel sign in determining outcome for decompression surgery in diabetic and nondiabetic neuropathy. *Ann Plast Surg* 2004;53(6):523-527
- Aszmann O, Tassler PL, Dellon AL. Changing the natural history of diabetic neuropathy: incidence of ulcer/amputation in the contralateral limb of patients with a unilateral nerve decompression procedure. *Ann Plast Surg* 2004;53(6):517-522
- Rader AJ. Surgical decompression in lower-extremity diabetic peripheral neuropathy. *J Am Podiatr Med Assoc* 2005;95(5):446-450
- Valdivia JM, Dellon AL, Weinand ME, Maloney CT Jr. Surgical treatment of peripheral neuropathy: outcomes from 100 consecutive decompressions. *J Am Podiatr Med Assoc* 2005;95(5):451-454
- Yao Y, Wang RZ. Peripheral Nerve Decompression (Dellon Procedure) and Diabetic Neuropathy. *Chinese J Med* 2005;10:1756-1758
- Siemionow M, Alghoul M, Molski M, Agaoglu G. Clinical outcome of peripheral nerve decompression in diabetic and nondiabetic peripheral neuropathy. *Ann Plast Surg* 2006;57(4):385-390
- Nelson SC, Little ER Jr. The 36-item Short-Form Health Survey outcome evaluation for multiple lower-extremity nerve decompressions in diabetic peripheral neuropathy: a pilot study. *J Am Podiatr Med Assoc* 2007;97(2):121-125
- Karagoz H, Yuksel F, Ulkur E, Celikoz B. Early and late results of nerve decompression procedures in diabetic neuropathy: a series from Turkiye. *J Reconstr Microsurg* 2008;24(2):95-101
- Dellon AL. The Dellon approach to neurolysis in the neuropathy patient with chronic nerve compression. *Handchir Mikrochir Plast Chir* 2008;40:1-10
- Dellon AL. Surgical treatment of chronic nerve compression in the patient with neuropathy. In: Zgonnis T, ed. *Surgical Reconstruction of the Diabetic Foot and Ankle*. Philadelphia: Lippincott Williams & Wilkins; 2009
- Dellon AL, Mackinnon SE, Seiler WA IV. Susceptibility of the diabetic nerve to chronic compression. *Ann Plast Surg* 1988;20(2):117-119
- Dellon ES, Dellon AL. Functional assessment of neurologic impairment: track analysis in diabetic and compression neuropathies. *Plast Reconstr Surg* 1991;88(4):686-694
- Dellon AL, Dellon ES, Seiler WA IV. Effect of tarsal tunnel decompression in the streptozotocin-induced diabetic rat. *Microsurgery* 1994;15(4):265-268
- Kale B, Yuksel F, Celikoz B, Sirvanci S, Ergun O, Arbak S. Effect of various nerve decompression procedures on the functions of distal limbs in streptozotocin-induced diabetic rats: further optimism in diabetic neuropathy. *Plast Reconstr Surg* 2003;111(7):2265-2272
- Siemionow M, Sari A, Demir Y. Effect of early nerve release on the progression of neuropathy in diabetic rats. *Ann Plast Surg* 2007;59(1):102-108
- Dellon AL. The four medial ankle tunnels: a critical review of perceptions of tarsal tunnel syndrome and neuropathy. *Neurosurg Clin N Am* 2008;19(4):629-648, vii
- Dyck PJ. Peripheral neuropathy. Changing concepts, differential diagnosis and classification. *Med Clin North Am* 1968;52(4):895-908
- Vinik AI, Mehrabyan A. Diabetic neuropathies. *Med Clin North Am* 2004;88(4):947-999, xi
- Sinnreich M, Taylor BV, Dyck PJ. Diabetic neuropathies. Classification, clinical features, and pathophysiological basis. *Neurologist* 2005;11(2):63-79
- Tassler PL, Dellon AL. Cutaneous pressure thresholds in ulcerated and non-ulcerated diabetic feet, measured with the Pressure-specified Sensory Device. *J Am Pod Med Assoc* 1995;85:679-684
- Tassler PL, Dellon AL. Correlation of measurements of pressure perception using the pressure-specified sensory device with electrodiagnostic testing. *J Occup Environ Med* 1995;37(7):862-866
- Dellon AL. Computer-assisted sensibility evaluation and surgical treatment of tarsal tunnel syndrome. *Adv Pod* 1996;2:17-40
- Tassler PL, Dellon AL. Pressure perception in the normal lower extremity and in the tarsal tunnel syndrome. *Muscle Nerve* 1996;19(3):285-289
- Vinik AI. Advances in diabetes for the millennium: new treatments for diabetic neuropathies. *MedGenMed* 2004;6(3, Suppl)13-19
- Rathur HM, Boulton AJ. Recent advances in the diagnosis and management of diabetic neuropathy. *J Bone Joint Surg Br* 2005;87(12):1605-1610
- Palumbo JP, Melton LJ. Peripheral vascular disease and diabetes. In: Harris M, Jammam R, eds. *Diabetes in America*. Washington, DC: U. S. Govt. Printing Office; 1985
- Moss SE, Klein R, Klein BE. The prevalence and incidence of lower extremity amputation in a diabetic population. *Arch Intern Med* 1992;152(3):610-616
- Resnick HE, Valsania P, Phillips CL. Diabetes mellitus and non-traumatic lower extremity amputation in black and white Americans: the National Health and Nutrition Examination Survey Epidemiologic Follow-up Study, 1971-1992. *Arch Intern Med* 1999;159(20):2470-2475
- Frykberg RG. Epidemiology of the diabetic foot: ulcerations and amputations. *Adv Wound Care* 1999;12(3):139-141
- Centers for Disease Control. *Diabetes Surveillance, 1993*. Atlanta, GA: U.S. Department of Health and Human Services; 1993

- 38 Bloomgarden ZT. American Diabetes Association 60th Scientific Sessions, 2000: the diabetic foot. *Diabetes Care* 2001;24(5):946–951
- 39 Centers for Disease Control and Prevention (CDC). History of foot ulcer among persons with diabetes—United States, 2000–2002. *MMWR Morb Mortal Wkly Rep* 2003;52(45):1098–1102
- 40 Singh N, Armstrong DG, Lipsky BA. Preventing foot ulcers in patients with diabetes. *JAMA* 2005;293(2):217–228
- 41 Crawford F, Inkster M, Kleijnen J, Fahey T. Predicting foot ulcers in patients with diabetes: a systematic review and meta-analysis. *QJM* 2007;100(2):65–86
- 42 Crawford F, McCowan C, Dimitrov BD, et al. The risk of foot ulceration in people with diabetes screened in community settings: findings from a cohort study. *QJM* 2011;104(5):403–410
- 43 Bartus CL, Margolis DJ. Reducing the incidence of foot ulceration and amputation in diabetes. *Curr Diab Rep* 2004;4(6):413–418
- 44 Witsø E, Lium A, Lydersen S. Lower limb amputations in Trondheim, Norway. *Acta Orthop* 2010;81(6):737–744
- 45 Vamos EP, Bottle A, Edmonds ME, Valabhji J, Majeed A, Millett C. Changes in the incidence of lower extremity amputations in individuals with and without diabetes in England between 2004 and 2008. *Diabetes Care* 2010;33(12):2592–2597
- 46 Al-Wahbi AM. Impact of a diabetic foot care education program on lower limb amputation rate. *Vasc Health Risk Manag* 2010;6:923–934
- 47 Rogers LC, Bevilacqua NJ. Organized programs to prevent lower-extremity amputations. *J Am Podiatr Med Assoc* 2010;100(2):101–104
- 48 Nickerson DS. Low recurrence rate of diabetic foot ulcer after nerve decompression. *J Am Podiatr Med Assoc* 2010;100(2):111–115
- 49 Lavery LA, Armstrong DG, Wunderlich RP, Mohler MJ, Wendel CS, Lipsky BA. Risk factors for foot infections in individuals with diabetes. *Diabetes Care* 2006;29(6):1288–1293