
4

Chapter Four

Groin Pain

“There is a *demon*
attached to my pubic bone!”

When Can I Have Sex Again?

Joan (not her real name) was an airline stewardess. She was born in the Caribbean. She was lively, and a real fun person to be with. She enjoyed intimate relationships. **That was before she had her hernia repair!**

Joan now lives in Boston. She is 31 years old. She thinks she may have gotten her hernia pushing those heavy beverage and food carts in the airplanes. She had her left inguinal (groin) hernia repaired in March of 2001. She awoke with horrible stabbing pain in her groin area. The pain never went away.

Her doctor, an experienced general surgeon, told her the surgery had no complications, and that the hernia was fixed. The incision was healing well. The piece of plastic mesh put into the hernia site to give it strength was not the source of her pain, he reassured her. He renewed her oxycodone (her narcotic pain medication).

Three weeks after the surgery, when the surgical pain should have been gone, the surgeon continued her pain medicine. He told Joan her left groin area might hurt a little while longer and to come back in 2 more months. He renewed her oxycodone. Joan was not able to return to work at the airline due to pain.

Three months after the surgery, when Joan still complained of pain in her pubic area and in the inside of her left thigh, her surgeon told her he still did not know why she was having pain. Joan showed him the spot that set off the pain. She could put her left index finger directly on the spot near her incision that set off the pain. He sent her for a special x-ray study, an MRI, of her pelvis. This showed that the hernia was fixed, and there were no new problems that could cause this pain. He told Joan she could work, if she wanted to work, and she should come back in three more months. He discontinued her oxycodone and told her to take Advil™, so she would not become addicted to the drugs.

Joan could not bend over without the pain. She could not wear a dress or pants with a tight top. Due to the pain in her groin, she was uncomfortable having intimate relationships. And stopped having them. She asked for a referral to a Pain Management doctor.

Joan finally came to be cared for by Dr. J (not his real name), a very successful Pain Management doctor in Boston. She continued trying different medications from the Pain Management doctor. He was very sympathetic. He tried giving her nerve blocks, and these actually relieved the pain, but only for a few hours. **This proved that pain was coming from an injured nerve.**

When the non-narcotic pain medications did not help her, she resumed taking narcotics, the type that had long lasting effects, throughout the day. Her income stopped. In time she had to leave her apartment and move in with relatives. She no longer had intimate relationships.

Joan became addicted to narcotics. She saw none of her old friends.

Three years after her hernia surgery, Dr. J. referred her to me. Dr. J. knew of my special interest, Peripheral Nerve Surgery, because he had a patient whom I had helped greatly the previous year. That patient was unable to move his toes, was reduced to a wheel chair from a very active life, and was dependent upon all forms of pain medication every day. That patient came to see me in Baltimore, where I am Director of the Dellon Institutes for Peripheral Nerve Surgery®. As a Plastic Surgeon, I have been trained to solve difficult, and often unique, problems. I devised a plan to correct the injured nerves that proved to be successful for Dr. J's patient with leg pain, and so now Dr J. felt comfortable to refer Joan to me.

Joan, accompanied by three family members, traveled to Baltimore to see me. On the wall in my office is an illustration of the different nerves that can cause groin pain. Each nerve pain territory is shown in a different color.

Joan pointed to the area of the chart (see Figure 4-1) that matched her pain. She then showed me the area that triggered her pain. When she would lie down, and when she would sit up, the pain came on intensely.

“I can help you with this Joan,” I said. “I can fix this problem.”

Cutaneous Nerves of the Thigh and Groin Regions

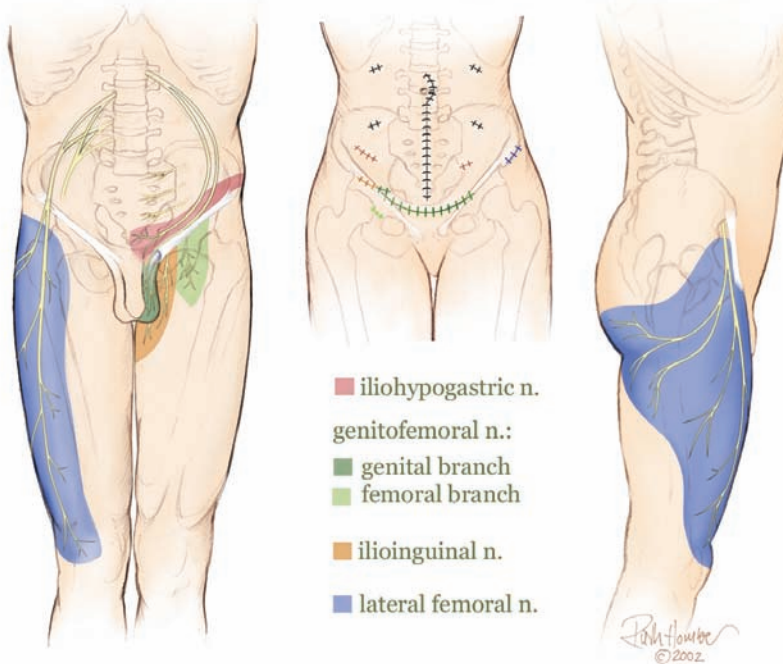


Figure 4-1. Groin Pain of Neural Origin. Each color represents the skin region innervated by the nerve represented by the same color. The scars represent typical operations, listed in Table 4-1. The location of the scar is in the same color as the nerve that is usually injured in that location. If your pain is related to these areas, then your pain is of neural origin. (with permission from <http://www.dellon.com>)

Her pain was due to an injury of the ilioinguinal nerve, a nerve that travels in the same area in which the hernia was repaired. This is the nerve that is the usual cause of pain after hernia repair, although there are four different nerves to consider. The nerve can become trapped in the sutures used for the hernia repair or become trapped in the mesh. When Joan would sit up or lie down, the nerve would be pulled by the muscles against the scar, setting off the pain. The temporary relief she obtained with the nerve block proved this to be true.

I explained that the surgery would take one hour, and would be done under general anesthetic. Joan would be an outpatient and could walk immediately after the surgery.

Joan asked the critical questions that concerned her: How soon would it be till she knew she was better? How long would it take her to be able to work again? How long would it be before she could have sexual intercourse again? I told her there were no guarantees of success, but there was a 90% chance she could resume her previous activities, and that Doctor J. would work with her then to reduce her dependence on drugs.

Joan consulted with her family. She decided to have the surgery.

I operated on Joan three weeks later. It was April of 2005. **Joan had been in pain for more than four years.**

At surgery, I made a new incision in front of her left hip bone. I found the ilioinguinal nerve, and removed it. There was no need to remove the mesh or disrupt the original hernia repair.

Joan awoke in the recovery room. When her mind began to let her appreciate her condition, she reached down and touched the trigger spot. **There was no pain.** But she vaguely remembered that I had told her I would put a local anesthetic into the skin so she would awake without pain from the incision itself. Then she pressed down really hard. **There was no pain!** Joan suddenly sat up on the stretcher in the recovery room. **There was no pain!** Her nurse saw her sit up, and, fearing some medical emergency, came quickly to her side. Joan whispered something to the nurse. I had just come back into the recovery room to check on Joan. The nurse looked up in surprise, as Joan, with a wide-eyed stare, and a smile, repeated her question loudly:

“When can I have sex again?”

Dave’s Groin Pain

Dave L. (not his real name) works in Hollywood. He is a writer and a director. He does his homework. When his right groin pain was said to be due to an inguinal hernia, he did his research. He chose a general surgeon to do the hernia repair who used the latest approach. This approach did not

make an incision, but relied upon small “punctures” made through the abdomen, and through these holes (endoscopic sites) corrected the hernia by placing a piece of plastic mesh into the weak abdominal wall. The mesh is held in place by small “tacks.” The surgeon had done this procedure many times without problems. In fact, he was known to have done this on many famous Hollywood “stars.” So Dave signed up to have his hernia fixed by this experienced surgeon using an endoscopic mesh technique.

In 1996, Dave went to sleep with his dull, aching, right groin, hernia pain. He had puncture wounds placed near his belly button and in his right groin to permit the hernia repair with the mesh and the tacks. Although his surgeon was to tell him later that the surgery went “perfectly and without complications,” Dave says he awoke with “*a demon attached to my pubic bone.*” His pain never stopped.

Dave, like Joan mentioned earlier in this chapter, went through the ritual of wound healing pain, normal post-operative pain, prolonged surgical pain. He went through the sequence of pain medication to chronic pain medication. He went to other surgeons for second and then third, and then fourth opinions. He went to the famous West Coast Universities of Stanford and UCLA, seeking answers from neurologists, radiologists, surgeons, and finally pain management doctors. Dave became depressed, disillusioned with the medical profession, and a typical chronic pain patient.

Dave was told that his pain was due to a nerve injury, but that he should not have that nerve cut.

Dave bravely showed his x-ray to anyone who would look and listen (see Figure 4-2 for a similar x-ray.). The x-ray that showed the metal tacks, he was told, did not mean that any of those tacks was the source of his pain, even though one of those tacks was exactly where he felt the “demon” was gnawing on his pubic bone.

Dave could no longer do creative writing due to his pain, and he dropped off the Hollywood radar screen. Dave could no longer maintain the loving relationship with his wife due to his chronic pain. His personality changed.

He no longer derived pleasure playing with his young son. His wife went back to work as a lawyer to provide an income for their family.

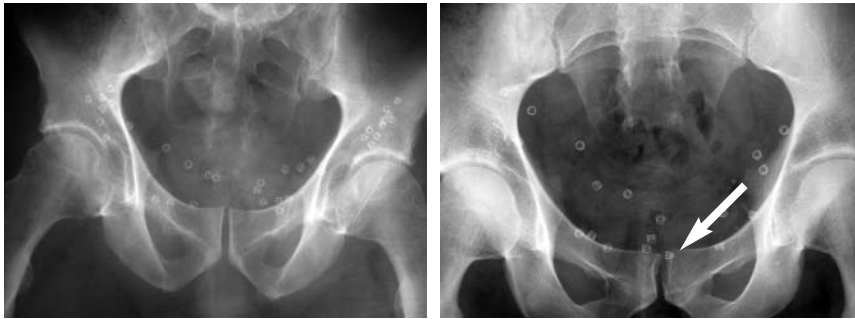


Figure 4-2. X-ray examples of patients who each had endoscopic bilateral hernia repair using plastic mesh and metal tacks to hold the mesh. These tacks may painfully impinge a nerve against a bone (arrow), or encircle the nerve beneath the skin.

Dave grew a beard, and began to search the internet looking for the help that he prayed was out there, somewhere. The internet located a scientific paper written by A. Lee Dellon, MD, a Plastic Surgeon in Baltimore. Doctor Dellon had begun to identify the relationships between the nerves that innervate the groin, and groin pain of neural origin. Dave e-mailed me for help.

I asked Dave by e-mail if he could point to an area that set off the pain. He replied “yes, but no one is willing to operate on me again to remove a nerve or a metal tack.”

I replied by e-mail “There is hope for you. I can help you.” I asked Dave to come to Baltimore to see me. He said he was in too much pain to fly. I was scheduled to lecture at a University in San Francisco shortly thereafter, and asked Dave if he thought he could make the trip from LA to San Francisco. Dave came up from LA to see me. I listened to his story, reviewed the x-ray, and examined him.

“I can help you Dave,” I said. “I want to propose a special approach to solve this problem for you. There are so many tacks and I want to be sure to remove the right one.”

“What approach will you use,” Dave asked?

I explained that the surgery would begin with Dave under twilight sleep, while I used a local anesthetic to make the skin numb for the incision. Then the anesthesiologist would wake him up sufficiently so that he would know I was touching him inside the wound. Dave would then tell me his pain level as I explored the depths of the wound to find the tack. When I had touched the exact trigger spot for his pain he would tell me. Then the anesthesiologist would put him completely to sleep and I would remove the tack in that location. The intravenous medications would remove the memory of most of this experience for him. Dave agreed to the plan, and flew to Baltimore.

The surgery was in October of 1999. **Dave had been in pain for three years.** Dave awoke from surgery and smiled. **He knew immediately.** “**The demon is gone.**” He went back to the West Coast.

In three months he was off his narcotic medications, and his head and creative powers returned. He began writing again for a major studio. He regained his strength. He wrote to me.

“My wife and I are like back when we were in college, having enjoyable sex regularly.”

Later that year, Dave sent me, a Holiday Card, with a photo of himself, his wife, and his son, wearing their ski gear. They had gone to Lake Tahoe, and were standing on the mountain on the California trail, with views of both California and Nevada. Dave wrote on the card,



Figure 4-3. Smiling Dave, lifting a log in his workshop, 6 years after Dellon procedure for groin pain.

“My family and I are on the top of the world again, thanks to you.”

In 2005, Dave and I connected again by e-mail. He sent me a picture of himself, carrying a large tree trunk in his wood working shop at home. He could lift, use power tools, and give in fully to his creative spirit. A wide smile shown though his beard. Still free of groin pain 6 years and counting.

Hernia Surgery and Groin Pain Statistics

It has been estimated that there are 700,000 hernia repairs done each year in the United States. Scientific outcome studies in 2001 and 2003 found that about 50% of patients after hernia repair have some degree of prolonged pain, and that 25% have pain for more than one year.* **One in eight patients have functionally disabling pain more than one year after hernia repair.****

What Types of Surgery can cause Groin Pain?

The types of surgery that may result in groin pain are given in Table 4-1. Any incision in the lower abdomen or upper thigh may injure a nerve and result in groin pain.

Table 4-1.

Types of Operations that can Cause Groin Pain due to Nerve Injury:

Abdominoplasty	Hysterectomy
Angioplasty	Hernia Repair
Breast Reconstruction (tram flap)	Femoral Inguinal (with or without mesh)
Cardiac Catheterization	Ventral Abdominal Wall
Femoral Artery Surgery	Ileostomy/Colostomy
Gastric By-Pass	Orchiectomy

*Bay-Nielsen, *Annals of Surgery*, 233:1-7, 2001, and Rutkow, *Surgical Clinics of North America*, 73:413-426, 2003.

**Dellon, A.L., *Invited Discussion of Pain Complications after Hernia Repair World Journal of Surgery*, 31:421-422, 2007.

Are the Groin Nerves Important to Me?

None of these nerves are functionally important. *They do not control motor function. They do not control erection or ejaculation. They do not give sensation to the penis or clitoris.*

Once this is understood, it remains to identify which nerve is the source of pain and develop a strategy to remove this injured nerve.

Where is the Groin?

Where exactly is your groin and what nerves are involved? Figure 4-1 shows the area from the front of your hip bone (anterior superior iliac crest) to your inner thigh, which includes your pubic area. The different colors are anatomic areas that related to four different nerves. Each of these nerves can be injured by an operation. The operative site is shown as a scar.

It is important to understand that the nerves to the groin begin inside the pelvis, come around the inside of the abdominal wall to enter the skin. These nerves can be injured by surgery that is done along the pathway of the nerve.

The pain is felt in the skin innervated by the nerve. The scar can be painful because that is where the nerve is injured, and this is considered as the trigger spot for the pain. As an example, touching the hernia scar may cause the pain which is perceived to come from the inner thigh skin. The thigh skin itself might be numb, or might be painful when touched.

In the approach that I developed, a new incision is made near the iliac crest, the “hip pointer” area (Fig 4-17). I do not go through the old scar. The small nerves causing the pain can be identified here and relocated out of the abdominal wall, and put back into the pelvic area where they arise.

Hysterectomy and Abdominoplasty

Harriet D. needed to have a hysterectomy.

She had gained sufficient weight that at age 55 she had a larger bulging lower abdomen than she wished. She did not like how she appeared in tight clothes. So her Gynecologist referred her to a Plastic Surgeon. He agreed

that her abdominal musculature was weak, and that she had sufficient excess skin that she would appear much improved if he tightened her abdominal wall muscles and removed the excess skin. He explained this would leave an incision longer than the Gynecologist would have left for the hysterectomy alone, and she would also have a scar around her belly button (umbilicus). The “makeover” plan was therefore to do a hysterectomy and an abdominoplasty at the same operation.

Harriet agreed. The surgery went without a problem. Harriet awoke with a feeling of tightness in her lower abdomen, as expected.

Two weeks later Harriet noticed that her abdomen did not feel tight any longer. But the incision on the right side was opening due to a localized infection, and her right thigh was numb. Her thigh became painful when she would sit. Her scar became thick and painful when touched (see Figure 4-4).

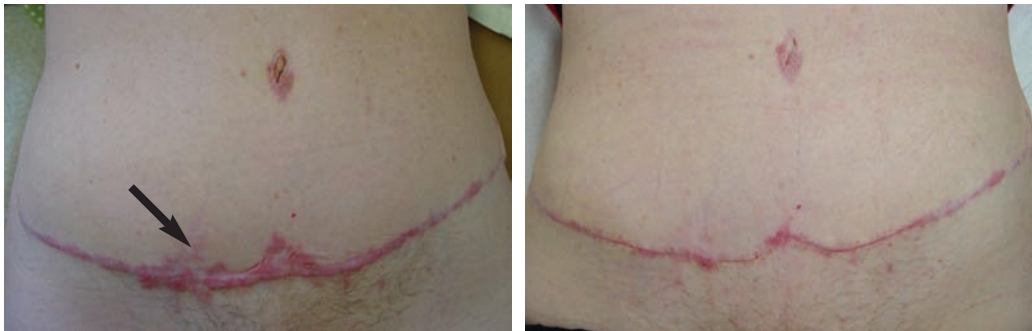

Figure 4-4. On the left, Harriet is shown 4 months following her abdominoplasty and hysterectomy combined procedure. There were wound healing problems on the right side, as noted by the thickened scar. **The arrow shows the site at which the scar was painful due to a neuroma of the ilioinguinal nerve.** Her condition after a Dellon-designed procedure is shown on the right. This appearance is at 14 days following scar excision, removal of the painful ilioinguinal nerve, and neurolysis of the lateral femoral cutaneous nerve (which causes numbness in the blue region shown in Figure 4-2 above). **This surgery immediately relieved her pain and improved her appearance cosmetically at the same time.**

Harriet's Plastic Surgeon referred her to me. He was aware of my research into groin pain, and the fact that the small nerves of the abdominal wall can become damaged by scar and cause groin pain.* He also was aware, through my writings in the Plastic Surgery literature,** that entrapment of a nerve near the hip bone can cause numbness in the front and side of the thigh.

I saw Harriet 7 months after her "makeover." From her complaints, of a painful scar, it was clear that she had a neuroma of the ilioinguinal nerve, and possibly also the iliohypogastric nerve, since the first surgical procedure went high up on the abdominal wall. Nothing further was required in terms of testing to determine this then to do the physical examination, which identified the painful area of the scar in the area that had opened (see Figure 4-1). X-rays do not show these small nerves, even the newest MRI can not show these nerves, which are just 1 or 2 mm in size.

It was clear from Harriet's complaints that the front of thigh bothered her, and was made worse with sitting. I believed she might also have compression of the lateral femoral cutaneous nerve (LFC), the nerve next to the hip bone (blue color in Figure 4-1). To document this, she had neurosensory testing with the Pressure-Specified Sensory Device™ (PSSD) This is a painless test, using a computer-linked measurement of pressure perception. In fact, I invented the PSSD in 1989 in order to be able to measure the function of the sensory nerves for problems such as this (more on the PSSD in Chapter 1, on Neuroma, Nerve Compression & Neuropathy).

*Liszka, TG, Dellon, AL, Manson PN; Iliohypogastric nerve entrapment following abdominoplasty. *Plastic Reconstructive Surgery*; 93: 181- 183, 1994.

**Nahabedian, MY, Dellon, AL, Meralgia paresthetica: Etiology, diagnosis, and outcome of surgical decompression, *Annals Plastic Surgery*, 35:590-594, 1995.

Harriet's test result, shown in Figure 4-5. It demonstrated no two-point discrimination in the right thigh region innervated by this nerve. This meant that the LFC was dying. A neurolysis or the LFC was needed.

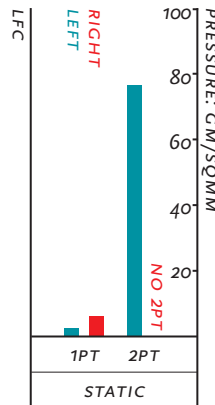


Figure 4-5. Harriet's neurosensory testing result. The Pressure-Specified Sensory Device™ demonstrated no right (red) two-point discrimination (2PT) in the region of the right lateral femoral cutaneous (LFC) nerve. There is still some function of this nerve as demonstrated by the normal height of the red one-point static touch (1PT). This documents a severe degree of nerve compression. The left side (blue) documents normal measurements.

I operated on Harriet, removing the previously poorly healed scar, removing the two nerves to the skin that were responsible for her pain, the ilioinguinal and iliohypogastric nerves, and saving the lateral femoral cutaneous nerve by doing a neurolysis.

Harriet awoke from this operation knowing that her thigh had its usual feeling restored. When she touched her previously painful scar the next day, it no longer hurt. She was better. The appearance of her abdomen is shown in Figure 4-4 (right) at the time of her suture removal, 14 days after the surgery.

Gastric By-Pass and Abdominoplasty

In the year 2005, it was estimated by the American College of Surgeons that there will be 120,000 surgical procedures performed to help people lose weight. Surgery to lose weight is called bariatric surgery.

Gastric by-pass surgery, or gastric stapling are forms of bariatric surgery that reduce the capacity of the stomach to hold food.

Being severely overweight threatens life itself. Bariatric surgery is successful in accomplishing significant weight loss in most patients. Like all surgery, there are potential complications.

Probably the most natural outcome of this surgery is that the skin cannot shrink up, leaving loose, hanging skin, especially in the abdomen. As noted for the patient described above, Harriet, Plastic Surgery can reduce this excessive skin. For Harriet, a traditional abdominoplasty was needed. After gastric by-pass, with loss of 100 pounds or more, skin must be removed from both the horizontal dimension (as Harriet had done) and from the vertical dimension, as Sandra needed to have done (see Figure 4-6).

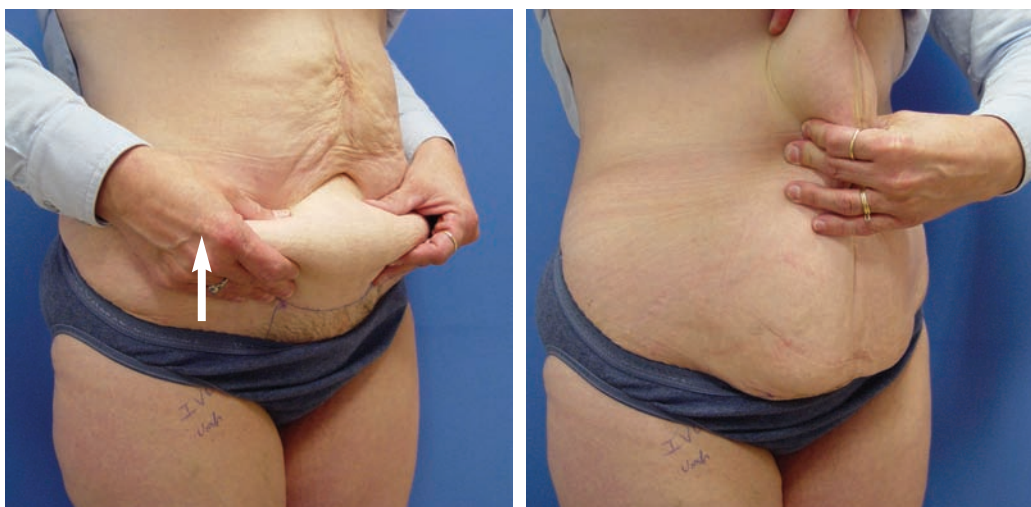

Figure 4-6. Sandra, after loosing 145 pounds, 1.5 years after gastric by-pass surgery. Left: shows vertical excess skin. Right: The horizontal excess skin that can be removed by a Fleur-de-Lys abdominoplasty, described by A. Lee Dellon, MD in 1985.* The arrow points to the site of her groin pain related to insertion of the caval umbrella.

*Dellon AL: Fleur-de-lis abdominoplasty. *Aesthetic Plast Surg* 9:27-32, 1985.

Another complication of being overweight and having bariatric surgery, is the risk of a blood clot forming in the leg, and then moving into the lung. This deep vein thrombosis and subsequent pulmonary embolism can be life threatening. For this reason, at some centers for bariatric surgery, a thin, metal “umbrella” is inserted into the vena cava, the large vein bringing blood to the heart from the legs. This caval umbrella is inserted through the large femoral blood vessels in the groin.

Sandra’s pain began when the umbrella was inserted through her right groin into her vena cava. The pain went into her inner thigh, and stayed there. She was told it would go away. The next day she had her gastric by-pass surgery (see Figure 4-7).

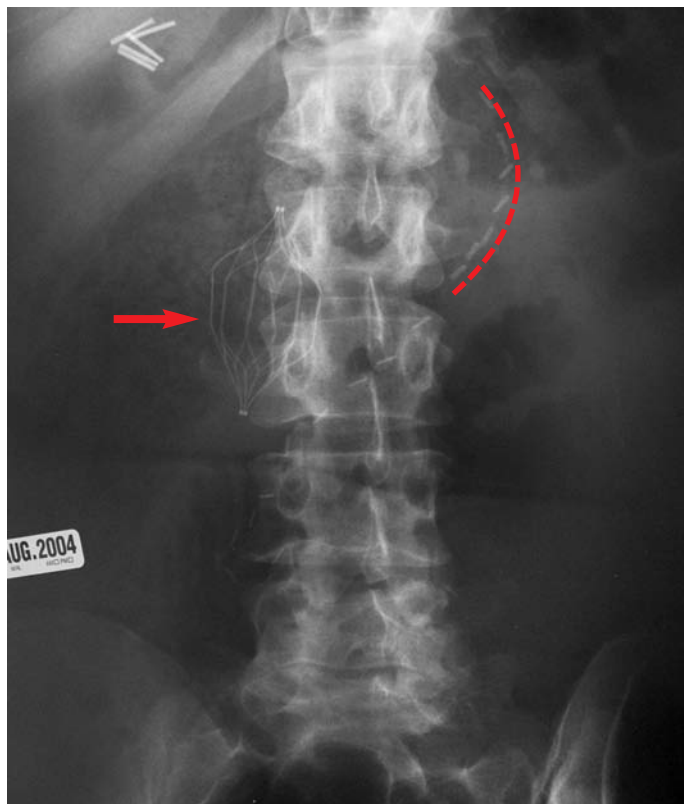


Figure 4-7. Sandra’s post-operative x-ray of her abdomen demonstrates the curved row of staples on her stomach (red dashed line), and the “umbrella” placed into her vena cava to prevent blood clots from reaching her heart (red arrow). Vascular clips are upper right. The metal umbrella was placed through her right groin, injuring a nerve.

Sandra's by-pass was successful. In 18 months she lost almost half her weight, going from 290 pounds to 135 pounds. But she remained in pain.

Sandra required narcotic medication for her right groin pain. She was prevented from enjoying the new thinner self she had become because of her constant pain. She was unable to play with her children or enjoy activities with her husband.

I operated on Sandra to relieve her of the groin pain by removing the damaged nerve. At the same time, I did her abdominoplasty.

Sandra awoke without the groin pain that had prevented her carrying out even the regular activities of her daily life. And she loved the appearance of her new abdomen too (Figure 4-8).

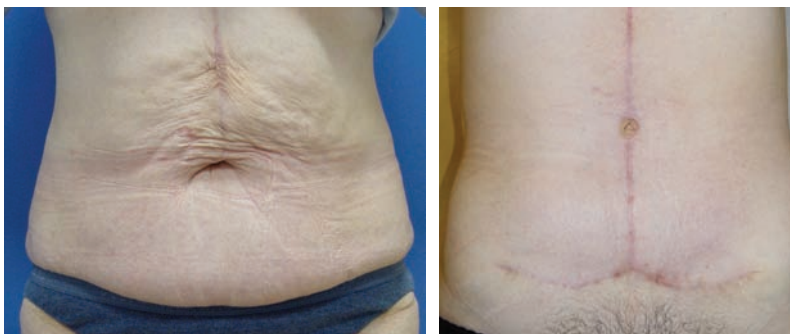


Figure 4-8: Sandra. Left: before surgery. Right: 6 weeks after a Fleur-de-lis abdominoplasty that improved the appearance of her abdomen after gastric by-pass surgery. Surgical exposure used to remove excess skin also allowed removal of the damaged nerve that caused her groin pain.

Painful Scar after Hysterectomy

Gynecologists are experts at operating on pelvic problems for women.

Gynecologists make the low, “bikini cut” incision hundreds of thousands of times a year in the United States. It is done for hysterectomy. It is done for Caesarian sections (to deliver babies). It is used for bladder suspensions for urinary incontinence. This incision is well-hidden and usually painless. Many Gynecologists have not had a painful scar.

The ilioinguinal nerve and the iliohypogastric nerve can send branches into this area to innervate the lower abdominal wall and the pubic, hair bearing, skin.

I have helped relieve pain in many women who have pain in these scars. Usually, I must remove both of these nerves. Examples are given in Figure 4-9 and 4-10 below.

The surgery is performed with a general anesthetic. The surgery takes about one hour for each side. The pain is gone usually upon awakening. Normal activities can be resumed the second day. The sutures are removed on the 12th to 14th day. The inner thigh, pubic hair area, and lower abdominal wall will have abnormal sensation, but it may not be much different than what you have.

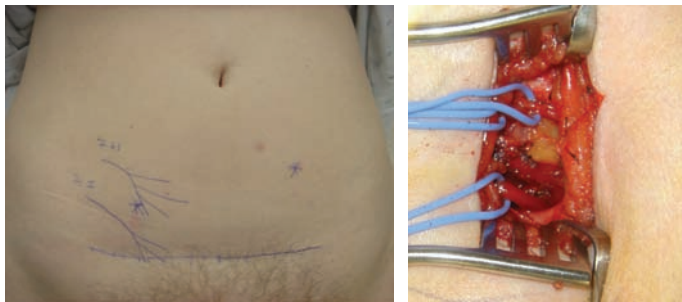


Figure 4-9. The typical Pfannenstiel incision (bikini cut) is shown above. It is the type used for hysterectomy and for Cæsarian-section. This incision can be a source of pain. Left: The pathways for the ilioinguinal (I.I.) and for the iliohypogastric (I.H.) nerves is shown going towards the scar. An old, pale, appendectomy scar is noted. The asterisks are trigger spots for the I.H. nerve, which is injured bilaterally (both sides) in this patient. Right: The incision is opened and the blue plastic loops show the I.H. (top) and the I.I. (bottom) nerves going into the scar.

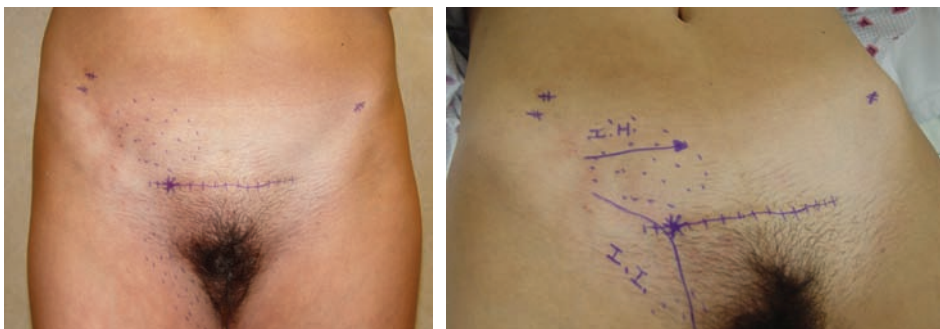


Figure 4-10. The painful hysterectomy scar. Left: The areas of numbness in the inner thigh, typically supplied by the ilioinguinal nerve, and that in the lower abdominal wall typically supplied by the iliohypogastric nerve. The asterisk in the incision is the trigger spot. The other small scars are sites where an endoscope punctured the skin to treat endometriosis. Right: The arrows show the pathways of the I.H. and I.I. nerves.

Testicular Pain after Orchiectomy

Removal of the testicle is called an orchiectomy. The thought alone is painful. The testicle may be removed for cancer or chronic infection.

When the testicle is removed, its nerve, the genital branch of the genitofemoral nerve (GF) must be cut. If a person perceives pain in the testicle, that pain is transmitted by this nerve.

The GF nerves exits the abdominal wall with the spermatic cord.

The GF nerve can be injured doing a hernia repair, because it is in the external inguinal ring, along with the ilioinguinal nerve and the hernia sac.

When the GF nerve is injured, the person complains of pain in the testicle. He does not complain of pain in the thigh or groin unless the ilioinguinal nerve is also injured. Which it often is.

Women do not have testicles. Women have ovaries.

Women do have a GF nerve. It goes to the inside of the labia majora, the vulva. It does not go to the vagina.

The underside of the scrotum is not innervated by the GF nerve, but rather by the perineal branches of the pudendal nerve. This nerve also innervates the external part of the vagina. The pudendal nerve exists between the legs, near the rectum, and is not in the groin.

James had just had 11 operations in 16 months.

At the first operation, his left testicle was removed. He had been treated by the best Urologists and Infectious disease specialists. His chronic infections of the small tubes around the testicle (epididymitis) could not be stopped. His profession as a motivational speaker had been on hold. His wife and three children were as supportive as possible.

James had severe, constant pain in his left testicle, even though he did not have a left testicle anymore.

One of his specialists thought a hernia was present. He had the hernia repaired with mesh. **His pain spread to include his inner thigh.**

He had the mesh removed.

He had a bleeding problem into the hernia site after removing the mesh. The blood had to be drained. Then this area became infected, and his wound had to be drained again.

James went to a Pain Management doctor. Local anesthetic was injected into his spine (epidural catheter) on several occasions. This was done in the operating room each time. He was even admitted to the hospital and the catheter was left in place for several days in his spine.

James became addicted to narcotics and unable to work.

Finally, the Pain Management specialist suggest that James have a spinal cord stimulator placed. This mean putting an electrical stimulator into James' spine, running the electrical cord around to the front of his belly, and implanting a small metal and plastic computer into his body. This helped a little. He went back to surgery to have the stimulator "repositioned" in his spine (see Chapter 10 on Stimulators). It did not really help him very much. He continued his medications.

And finally, the stimulator in the front of his belly became infected. Its pouch was drained. Then they had to remove the stimulator so that the infection did not spread along the wire into the spine. He was left with an open wound on his abdomen, which was to close slowly on its own over several months.

Have you lost count yet?

Mary, James' wife, found me on the internet. "Can you help us?" she asked. "We live in Virginia. I believe my husband can make the trip."

"I can help you," I replied. "Come on up!"

At the time I saw James, Figure 4-11 (left) is the appearance of his groin and abdomen. The drain is in the open wound which previously had held his spinal stimulator. He could point directly to the spot near his pubic bone where pain radiated to the testicle. He came prepared for surgery the next day, in case I could really help him. I had held a 2 hour space for James on my operating schedule in case I could help him.

“I can fix this for you James,” I said. At surgery, the genital branch of the genitofemoral nerve was at the external ring, where the Urologist had removed the testicle, and where the mesh and infection had been (Fig 4-12).

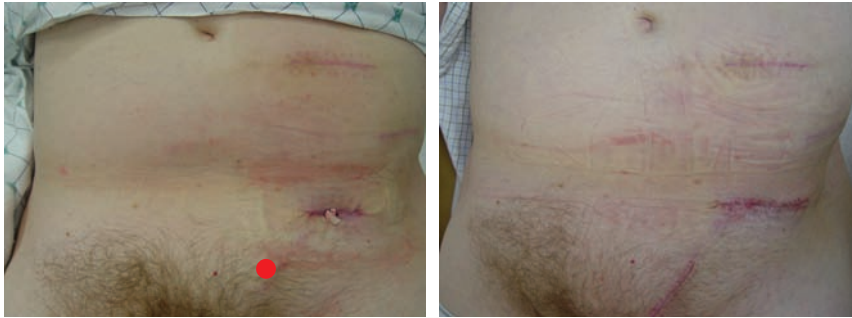


Figure 4-11. After 11 operations in 16 months, James, who first had his left testicle removed, has testicular pain localized at the red dot (Left) and a rubber drain in his abdominal wound where his spinal cord stimulator had been located. On the Right, 4 weeks after removal of the genitofemoral nerve through the pubic incision, removal of the ilioinguinal and iliohypogastric nerves through the incision near the hip bone, which was also used to excise the non-healing wound, the spinal cord stimulator site.

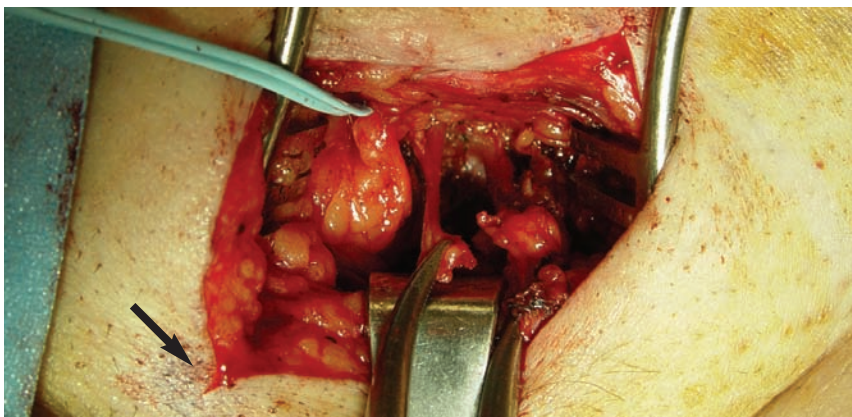


Figure 4-12. The clamp holds the genital branch of the genitofemoral nerve. The pain that signals testicular pain. The black arrow can be matched to red dot in Figure 4-11 at left.

James awoke from surgery without testicular pain.

James and Mary spent that night in the hotel across from the hospital, and I saw them the next morning. He had no bleeding. His wound was remaining closed. He had no more testicular pain. His scars no longer hurt.

James and Mary returned to see me 4 weeks later. He had no more testicular pain. His scar did not hurt. His wound remained closed (Figure 4-11 right). He had already switched from narcotics to anti-inflammatories, and was reducing his Neurontin dose. James is 60 years old. He had returned to work. Mary was happy too.

On November 16, 2005, I had this e-mail from James:

“Doctor Dellon, thank you. I am off all drugs and have resumed my regular activities and motivational speaking. Yesterday I walked 6 miles, and I ached a little. It is just 4 months since surgery. Am I doing too much? Before your operation I had terrible pain with intercourse and had lost most of my sexual function and desire. *Full function has returned, and it is like I am in my twenties again. Once again, sex is all fun and no pain (and several times per week). You have helped me beyond measure. Please tell people my story. It should give hope to others.*”

Cardiac Catheterization Caused Groin Pain

The exact number of cardiac catheterizations done each year in the United States must exceed half a million. It is likely that one of these will injure a nerve during placement of the catheter into the groin. Here is just one person to whom this happened.

Janis (not her real name) is a nurse in Ohio. She had chest pain one day at work. She had an EKG which was normal. Her cardiologist was worried, as Janis was under a lot of stress in her work and personal life. A near, dear relative had recently died. Janis was 52 years old. The Cardiologist sent Janis for a “stress EKG” test. As she was running on the treadmill, Janis had chest pain, although the EKG did not change. Faced with this puzzle, the Cardiologist felt it was best for Janis to have a cardiac catheterization.

During this test, done in the hospital, in a special Radiology Cardiac Center, using sterile technique, like a real operation, the Cardiologist or Radiologist insert a large metal needle into the femoral artery in the right groin. Through this, a small catheter is inserted all the way to the heart. Then x-ray dye is put in and a picture of the arteries of the heart is obtained.

Janis has a normal heart.

Janis now had groin pain.

The following pathway is now well known to you. Janis could point to a spot in her groin that set off the pain. The Cardiologist and Radiologist never had seen this problem before. Topical pain medication to the spot relieved the pain. Janis could not take narcotics and still function as a nurse. Janis had side effects from the non-narcotic, neuropathic pain medications, like Neurontin. Two years after her cardiac catheterization, Janis was sent by Pain Management to have a spinal cord stimulator placed.

The location of Janis's pain is shown in Figure 4-13. A picture of her back with its five incisions for placement of her stimulators is shown in Chapter 10 on Stimulators (Figure 10-3).

I operated on Janis, removing the femoral branch of the genitofemoral nerve. It was the source of her pain. She is pain free.

Her spinal cord stimulator has been removed.

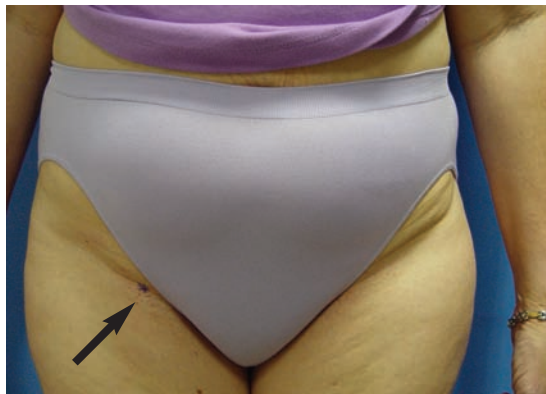

Figure 4-13. Arrow and blue dot mark the site of pain remaining 3 years after a cardiac catheterization. A spinal cord stimulator was placed, moved, and replaced. What was needed was removal of the painful neuroma.

Ileostomy and Groin Pain

When the intestine must be brought out on to the abdominal wall, the possibility of pain related to one of the nerves to the groin is real. It is unusual, but it is real. I have two patients with this problem. *How many more people are out there with groin pain after ileostomy or colostomy?*

Marcia (not her real name) is 75 years old. She is mentally sharp as a tack. She dresses beautifully. Her hair always looks like she has just come from the beauty parlor. A husband Marty (not his real name) is a lively 78. He will only have health care administered by the best people. Which in his view, is always someone trained at Johns Hopkins. He is a benefactor.

Her bladder cancer was treated with radiation therapy at a time when the exact dose to kill the cancer was not really known. That was 28 years ago. Her Hopkins Gynecologic Oncologist removed her bladder and uterus. The radiation killed the remaining cancer cells. **It also killed part of her intestine.** And so she had an ileostomy.

She is happy she is alive.

Then the radiation killed the skin of her lower abdomen. Plastic Surgeons at Johns Hopkins removed the dead skin, muscle and connective tissue. They then created a new lower abdomen for Marcia from the skin and muscle of her right leg. Plastic mesh was also required to strengthen the large abdominal wall defect. **When the flap was moved from the leg to the abdomen, it required a point of rotation in her right groin, The flap lived (see Figure 4-14). The abdominal wall and thigh were both closed again.**

Marcia's groin pain started shortly thereafter. The pain went from just below her ileostomy to the right groin, and into her thigh. She went to Pain Management doctors in Pennsylvania, trying to get relief. Her pain persisted for one year.

Finally she received my name from her Gynecologic Oncologist, the one who had saved her life with her initial tumor. He was from Johns Hopkins Hospital. He knew me. Indeed, he and I were residents together at Johns Hopkins Hospital in the late 1970's. He knew of my interest in nerves.

Marcia saw me. Marty was with her. **She could hardly climb on to the examining table because of pain.** She could hardly lie down flat to be examined. She felt much better if her leg was bent at the hip. I found her to have a trigger spot, below the ileostomy, near the iliohypogastric nerve. There was a trigger spot for the ilioinguinal nerve as well. Her entire front and side of her thigh had burning pain when the skin was touched.

“I can help you, Marcia,” I said. **We need to remove three nerves. They have been stretched and caught in scar tissue by the flap.**

“I will gladly trade numbness for pain,” Marcia said.

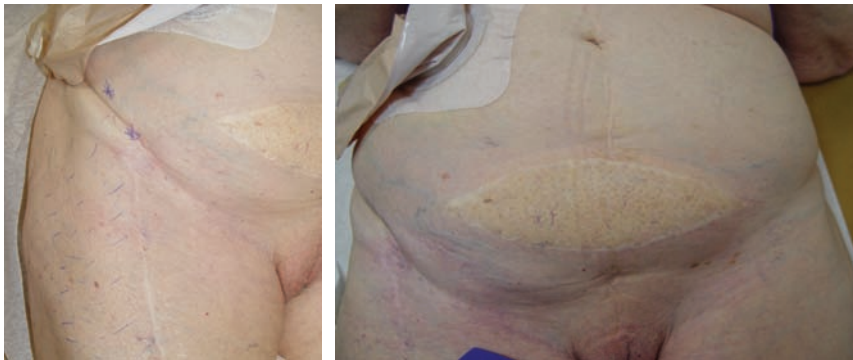


Figure 4-14. Marcia's right thigh (left), with long healed scar at the site where the leg muscle and skin were taken as a flap and rotated to reconstruct the lower abdominal wall (right). On the left, note the area of thigh pain outlined in blue, indicating damage to the lateral femoral cutaneous nerve. Near the ileostomy bag, not the trigger spots where the iliohypogastric and ilioinguinal nerves were caught in the flap rotation.

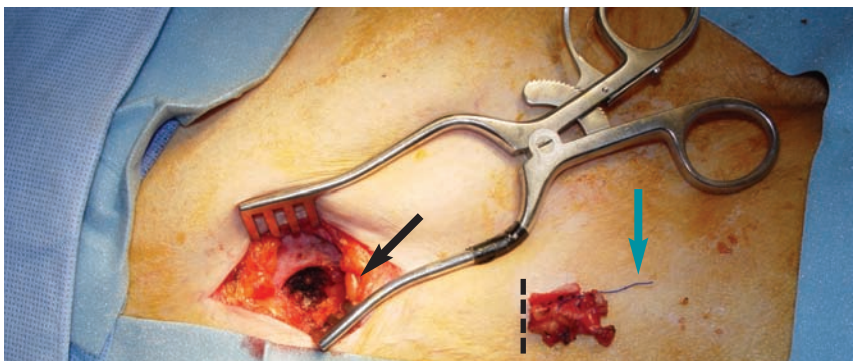


Figure 4-15. Marcia, intra-operative view. Note blue suture (blue arrow) attached to piece of mesh (dashed line) and the damaged lateral femoral cutaneous nerve (LFC, black arrow). The dark opening is the space the LFC nerve came through, and into which it was placed back inside the abdominal cavity.

At surgery, the lateral femoral cutaneous nerve was stuck in scar tissue to the mesh by a suture (Figure 4-15). The nerve was divided and dropped into her abdomen. The iliohypogastric and ilioinguinal nerves were also removed.

Two months after the surgery, Marcia and Marty came back to see me from Pennsylvania. Marcia said, “My pain is gone. My life is worth living again.”

Marty said, “My brother has knee pain after his knee replacement. Can you help him?”

“Yes,” I said (see Chapter 3 on Knee Pain).

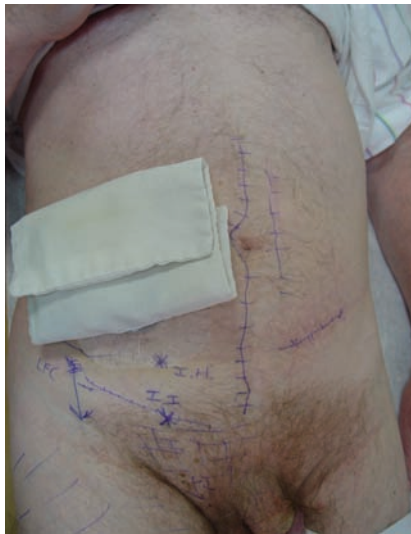

Figure 4-16. Another example of groin pain associated with ileostomy. A 48 year old man four years after bowel resection for ulcerative colitis. Has had many previous abdominal operations for his bowel problems. The bag can be seen on his ileostomy. He has numbness in the thigh, but not pain, and his lateral femoral cutaneous nerve can be saved with a neurolysis. His iliohypogastric nerve (I.H. trigger point) and ilioinguinal nerve (I.I. trigger point) will require resection of these nerves. He has come to the Dellon Institutes for Peripheral Nerve Surgery® from Holland, upon referral from the Chief of Plastic Surgery, Moshe Kon, in Utrecht. Dr Kon knew of my interest in peripheral nerves.

How many Nerves should be Removed?

From the above examples, I have tried to convey the complexity of deciding what to do for the patient with groin pain. The answer is not as simple as “always do a triple nerve resection.”

When the patient comes to me for a consultation, I listen to their exact complaints and learn where, during my physical examination, the trigger points for their pain are located.

There are four nerves to be considered. Usually the lateral femoral cutaneous nerve can be saved, but sometimes, as with Marcia (above), it may be so damaged that it must be removed. The genital branch of the genitofemoral nerve does not have to be removed unless there is clearly testicular pain present. Almost always, the ilioinguinal and iliohypogastric nerves must be removed. Figure 4-17 show two examples of patients who each only needed the ilioinguinal and iliohypogastric nerves removed.

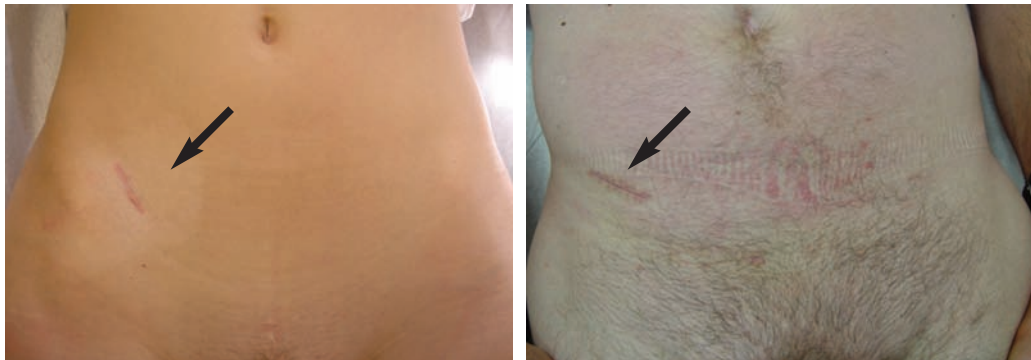

Figure 4-17. Examples of typical incision near the anterior superior iliac crest (black arrows) used to remove the ilioinguinal and iliohypogastric nerves.

Complex Groin Pain Patients

In the patient in Figure 4-18, the number of incisions in the abdomen speaks for itself. I was able to relieve this patient of pain by excision of the ilioinguinal and iliohypogastric nerves. This patient’s iliohypogastric nerve can be seen clearly.

Groin pain patients are complex, and each must be considered as an individual, and an individual surgical plan arrived at together.

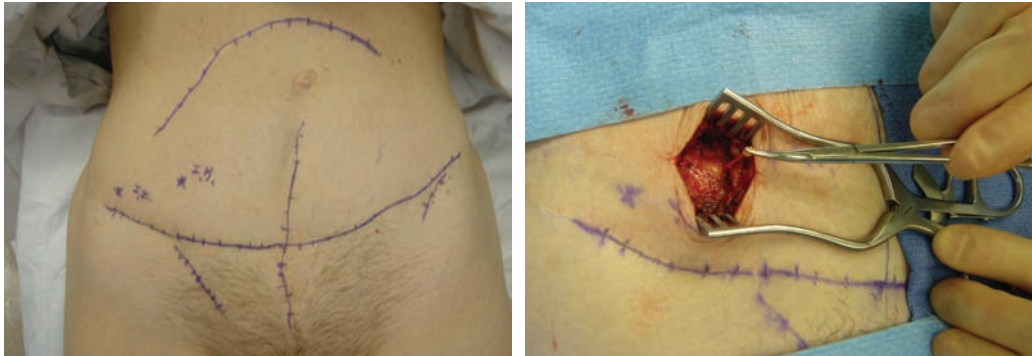


Figure 4-18. Right groin pain in 60 year old woman who has had many surgeries. Pain was relieved by resecting the ilioinguinal and iliohypogastric (held in clamp) nerves.

As a final example, consider the patient shown in Figure 4-19. He is a 26 year old man who has had bilateral inguinal hernia repairs. Mesh was used bilaterally. He has bilateral groin pain, worse on the left than on the right. He can point to his areas of pain, which are noted in the photographs. He did have left testicular pain. His surgery required ilioinguinal and iliohypogastric nerves to be removed bilaterally. He also needed the left genital branch of the genitofemoral nerve removed.

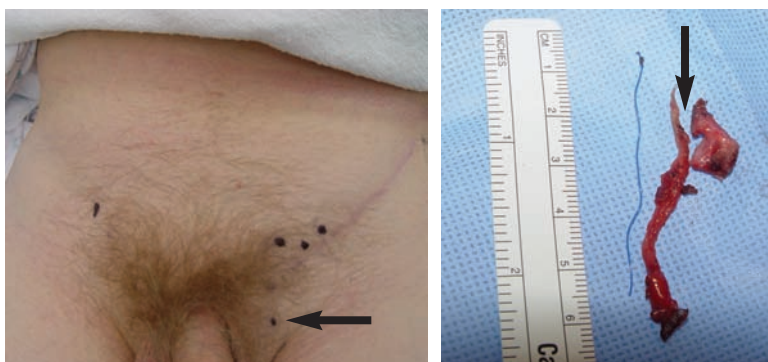


Figure 4-19. Left: The black dots indicate trigger points for the pain. On the left side, note the black dot over the spermatic cord in the pubic hair (arrow). This was the trigger spot for the genital branch of the genitofemoral nerve. Right: The nerve has been removed. It was found to have the blue suture connecting it to the mesh. Note the notch (arrow) in the mesh, which caused the testicular pain.

Tack this on at the End

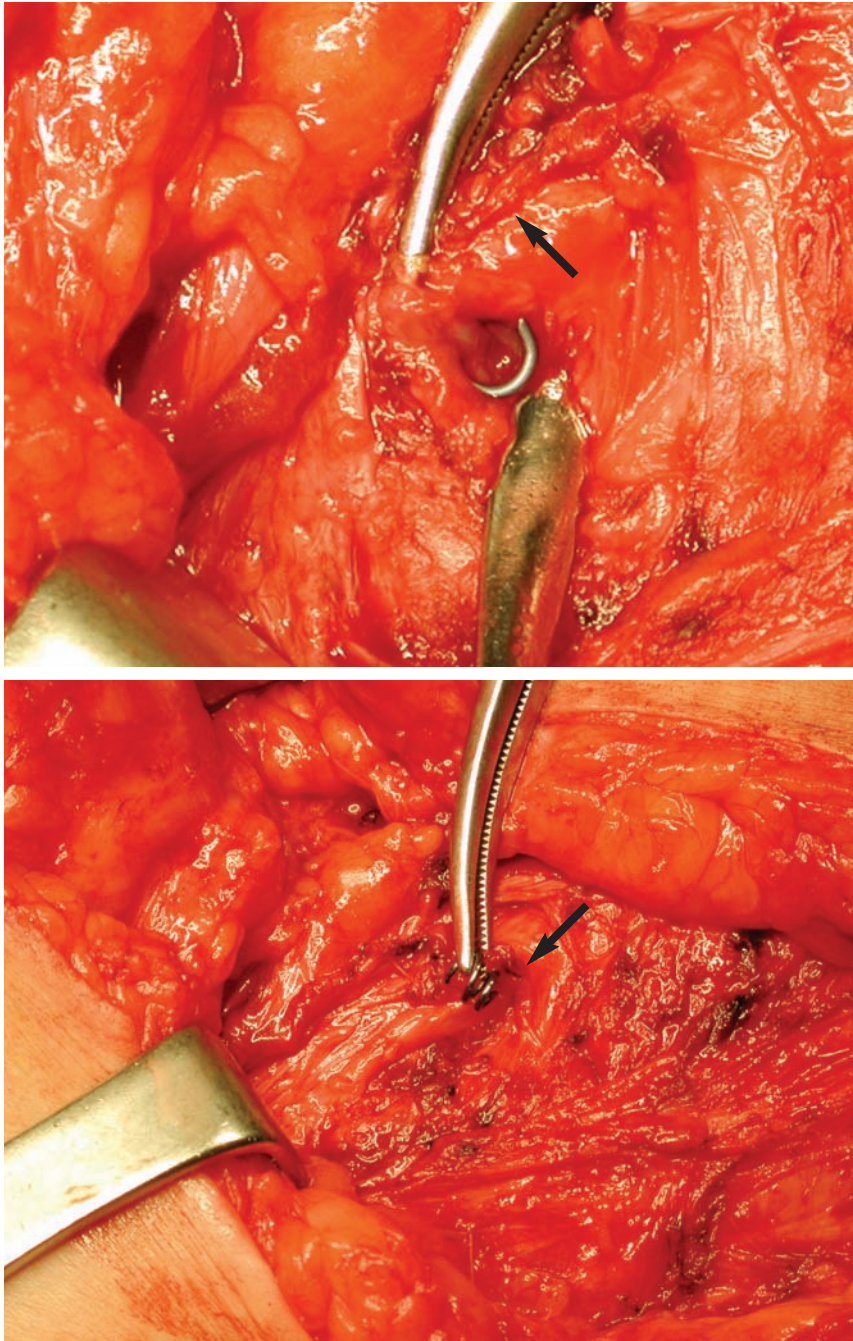


Figure 4-20. Mesh repair of inguinal hernia with mesh placed endoscopically. Top: The metal tack is noted encircling the ilioinguinal nerve and mesh (arrow). Bottom: The metal tack is held in clamp. The nerve is held in the tack (arrow).

Pain Solutions Summary

Groin pain after surgery or injury can be due to a nerve.

There are four different nerves that may contribute to your pain.

If it is more than 6 months from the time of your last surgery, and if medication and other therapy measures have not relieved your pain, then the solution to your groin pain problem most likely involves removing one or more of the nerves that are causing your pain.

Where can I learn more about Groin Pain?

On the internet, the Dellon Institute for Peripheral Nerve Surgery® website has more information and a BROCHURE on *Groin Pain* that can be downloaded at <http://www.dellon.com>

You can call the HOTLINE at +1 877-DELLON-1 (+1 877-335-5661).

